Bariatrics downsized

Beth Murgatroyd, London Weight Loss Surgery

SINGLE INCISION LAPAROSCOPIC surgery, where the operation is performed through one small abdominal incision, is slowly emerging as a favourite option amongst patients and laparoscopic enthusiasts. To date, a handful of surgeons are advocating this technique in general surgery, colorectal, urology and paediatrics. However, the world of weight loss surgery has been slow to adopt the single incision approach in part due to the technical challenges that larger patients pose, with hepatomegaly and central adiposity.

In 2008, having first sought approval from the local new and novel committee, Mr Ameet Patel, a Consultant Surgeon at King's College Hospital, and Princess Grace Hospital, initially undertook single incision laparoscopic cholecystectomies, swiftly followed by single incision splenectomy, appendicectomy, and liver resections. In October 2008 he embarked on bariatrics and to date has performed single incision laparoscopic sleeve gastrectomies, and over 130 true single incision laparoscopic gastric band operations.

Having acquired considerable single incision surgical skills, the final frontier to be conquered was the Single Incision Laparoscopic Roux-en-Y gastric bypass, which was successfully undertaken on 5th September 2010.

In this initial experience the patient was a 24 year old school teacher who had struggled with her weight for many years. At surgery her weight was 123kg with a BMI of 48. Her past medical history included one caesarean section, and a fatty liver confirmed on ultrasound.

A single incision was made into the abdomen, through which a port with four working channels was placed. Through this port a 5mm camera and standard laparoscopic instruments were used.

Mr Ameet Patel. The challenging ergonomics of the single incision approach.

The chosen post device was able to accommodate all equipment required, including the hand held liver retractor, harmonic scalpel and 10mm stapling device.

The operation itself was an exact replica of the laparoscopic approach, fashioning a 30ml gastric pouch, creating an anticolic gastrojejunostomy and entero-enterostomy and closure of mesenteric windows. The additional challenge that true single incision surgery poses for bariatric surgery is that of liver retraction and intra-corporeal suturing. However, our technique does not employ the use of external suturing for puppeteering of internal organs or placement or extra ports for liver retraction, and is truly single incision surgery. For this first attempt, operative time was 5 hours; however this time reduced by 2 hours for our second case, and continues to improve.

The final result was a single 38mm scar, and a patient reporting a low pain score over the following 3 days, with minimal pain at the wound site, rather manifesting as shoulder pain. Post-operative gastrograffin was satisfactory and the patient discharged on day 3 on a liquid diet as per normal protocol. At 6-week follow-up, the patient was absolutely delighted with her 15kg weight loss, her single incision scar, and excited to have been the first case!

Whilst we have demonstrated that with experience, the single incision laparoscopic roux-en-y gastric bypass is technically feasible, and has been repeated in 4 cases to date, just because we can do it – should we? As yet we have not demonstrated a clear advantage of a single incision –v- laparoscopic approach to surgery and randomised controlled trials are urgently needed. However, we continue to explore the benefits of single incision surgery in the bariatric patient group. And so where do we go from here - the Duodenal Switch?

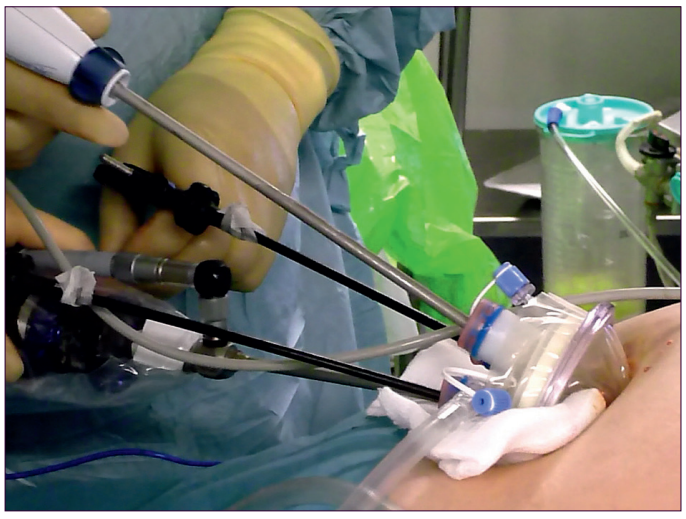

Four instruments in use through a single port

Single Incision Laparoscopic Roux-en-Y gastric bypass - All set and ready to go

The prodedure under way